

Review

## Phaeohyphomycosis in Korea

Moo Kyu Suh

Department of Dermatology, College of Medicine, Dongguk University  
Kyongju, 780-350, Korea

### Abstract

Phaeohyphomycosis is a mycotic disease caused by dematiaceous fungi that produce brown yeast-like cells, pseudohyphae, and irregular true hyphae in tissues. Seven Korean cases of subcutaneous phaeohyphomycosis have been reported to date, four males and three females, ranging in age from 9–84 years (mean 50.4 years). Causative organisms of subcutaneous phaeohyphomycosis were 3 of *Exophiala jeanselmei*, 2 of *E. dermatitidis*, 1 of *Drechslera dematioidea* and 1 of *Phoma* sp. Four cases of abscess and 3 cases of verrucous plaque were present as skin lesions, and were all exposed areas of the body. Patients were treated with itraconazole, ketoconazole, fluconazole or amphotericin B.

**Key words:** phaeohyphomycosis, Korea

### Introduction

Phaeohyphomycosis is a clinical term proposed by Ajello *et al.*<sup>1)</sup> in 1974 for mycotic infections that contain dematiaceous mycelial elements in tissue, and differs from chromoblastomycosis in that it has no sclerotic cells<sup>2–5)</sup>. These infections have been referred to as chromomycosis, phaeosporotrichosis, cerebral chromomycosis, phaeomycotic cyst, chromohyphomycosis, and systemic chromoblastomycosis<sup>2, 3)</sup>. McGinnis<sup>3)</sup> defined four forms of phaeohyphomycosis: superficial (black piedra, tinea nigra), cutaneous and corneal (dermatomycosis, mycotic keratitis, onychomycosis), subcutaneous, and systemic.

Subcutaneous phaeohyphomycosis has been commonly reported in Japan<sup>6, 7)</sup> but rarely in Korea. There have been several reports<sup>8–14)</sup> of subcutaneous phaeohyphomycosis in Korea, and I would like to discuss their causative organisms, clinical features and treatment in this report.

### Etiology

The number of fungi documented as etiologic agents of phaeohyphomycosis currently number at least 57 genera and 104 species<sup>4)</sup>. The etiologic agents of subcutaneous phaeohyphomycosis are predominantly *Exophiala* (*E.*) sp. and *Phialophora* (*P.*) sp., including *E. jeanselmei*, *E. dermatitidis*

and *P. verrucosa*<sup>2)</sup>. The most common is *E. jeanselmei*, followed by *E. dermatitidis*<sup>2–4, 15, 16)</sup>. They are considered to be saprophytes of plant material, wood and soil. Many patients with phaeohyphomycosis have lived in rural areas. Infection follows traumatic inoculation of fungi into the skin<sup>2, 3, 11, 12)</sup>. Among the seven Korean cases of subcutaneous phaeohyphomycosis, etiologic agents were: 3 cases of *E. jeanselmei*, 2 cases of *E. dermatitidis*, 1 case of *Drechslera dematioidea*, and 1 case of *Phoma* sp.

### Clinical manifestations

The skin lesion of subcutaneous phaeohyphomycosis is a solitary abscess or granuloma that forms at the site of probable trauma in an exposed area of the body. The most common exposed area is an extremity. Patients with phaeohyphomycosis are predominantly older males<sup>2, 3)</sup>. The clinical features in Korean cases of subcutaneous phaeohyphomycosis are summarized in Table 1. Patients comprised four males and three females with a mean age of 50.4 years (range 9–84). The ratio of male to female was 1.3 to 1. Among these seven Korean cases of skin lesions were: 4 cases of abscess (Fig. 1) and 3 cases of verrucous plaque, and the sites of lesions involved were 3 cases of forearm, 3 case of face & neck, and 1 case of foot.

### Mycology

Black-gray velvety or yeast-like colonies are noted on the culture from biopsied tissue

Corresponding author: Moo Kyu Suh, M.D.

Kyongju, 780-350, Korea

Department of Dermatology, Kyongju Hospital,  
College of Medicine, Dongguk University

Table 1. Clinical features in the Korean cases of subcutaneous phaeohyphomycosis

Author (Year)	Sex/Age	Duration	Site	Skin lesion	Symptom	Causative organism	Tx
Jun & Suh <sup>8)</sup> (1983)	M/19	7 years	face	verrucous plaque	—	<i>Phoma</i> sp.	AMP-B
Lee <i>et al.</i> <sup>9)</sup> (1986)	M/34	7 months	neck, axilla	cystic mass	—	<i>Exophiala dermatitidis</i>	KCZ
Oh <i>et al.</i> <sup>10)</sup> (1996)	M/9	7 years	foot	verrucous plaque	pruritic	<i>Drechalera dermatioidea</i>	ICZ
Kim <i>et al.</i> <sup>11)</sup> (1998)	M/84	3 months	forearm, wrist	abscess	asymptomatic	<i>Exophiala jeanselmei</i>	—
Suh <i>et al.</i> <sup>12)</sup> (1999)	F/66	4 months	forearm	cystic mass	mild tender	<i>Exophiala jeanselmei</i>	ICZ
Kim <i>et al.</i> <sup>13)</sup> (1999)	F/66	1 month	cheek	scaly plaque	pruritic	<i>Exophiala dermatitidis</i>	ICZ
Suh <i>et al.</i> <sup>14)</sup> (2004)	F/75	8 months	forearm	abscess	asymptomatic	<i>Exophiala jeanselmei</i>	FCZ

AMP-B: amphotericin B, KCZ: ketoconazole, ICZ: itraconazole, FCZ: fluconazole

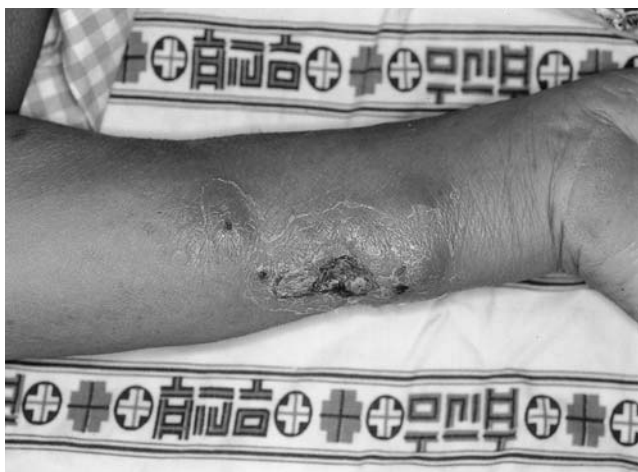

Fig. 1. 4.5 × 3.5 cm sized, erythematous cyst mass with satellite lesions on the left forearm.

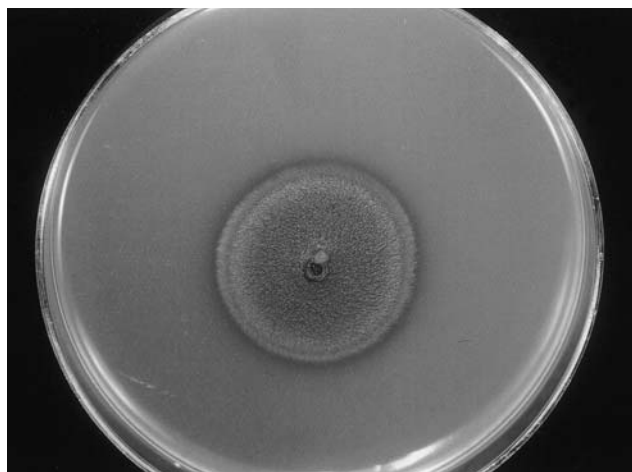


Fig. 2. Black-gray velvety colony of *E. jeanselmei* on Sabouraud's dextrose agar at 25°C for 2 weeks.

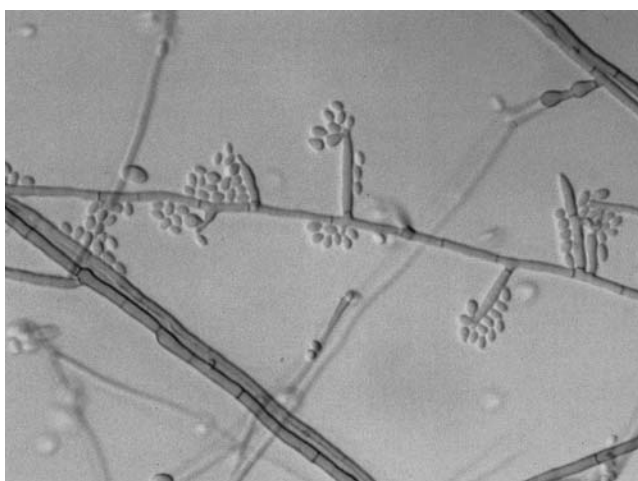


Fig. 3. Conidia at the apices of annellidic conidiogenous cells having pointed tip were shown in slide culture of *E. jeanselmei* (Lactophenol stain, × 400).

specimens placed on Sabouraud's dextrose agar at 25°C for 2 to 4 weeks in patients with phaeohyphomycosis<sup>2, 3)</sup> (Fig. 2). The dematiaceous fungi have been identified and classified by morphological, biochemical, and physiological tests<sup>2, 17)</sup> (Fig. 3). Molecular analysis has recently been introduced to the field of medical mycology<sup>18-20)</sup>. All Korean cases of subcutaneous phaeohyphomycosis showed the same mycological findings.

### Pathology

Histopathologically granulomatous inflammation with or without abscess and dematiaceous fungal elements in tissues of patients with subcutaneous phaeohyphomycosis are observed on Hematoxylin-eosin (H & E) staining (Fig. 4). Fungal elements are also visible on Periodic acid-Schiff (PAS) & Gomori methenamine silver

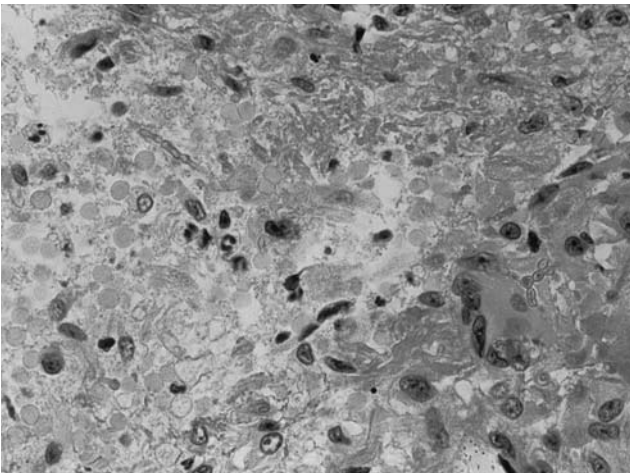


Fig. 4. Granulomatous inflammation with brownish conidia and hyphae in the deep dermis (H & E stain, × 200).

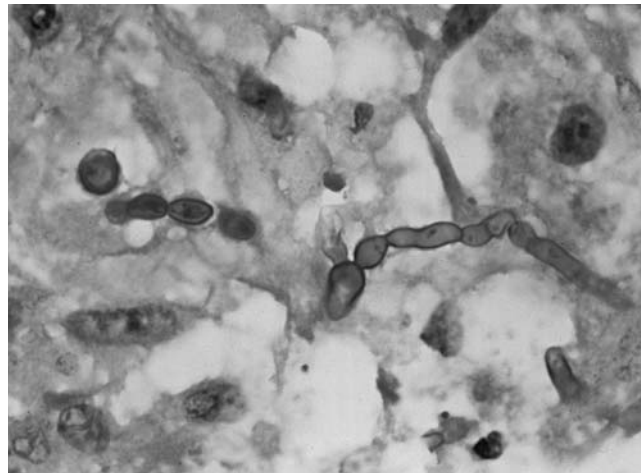


Fig. 5. Conidia in a chain and hyphae around giant cells (PAS stain, × 400).

(GMS) stain (Fig. 5), but sclerotic cells are not visible<sup>2, 3)</sup>. All Korean cases of subcutaneous phaeohyphomycosis showed the same histopathological findings.

#### Treatment

Subcutaneous phaeohyphomycosis is usually treated by surgical excision. There have been reports of its successful medical treatments by itraconazole, ketoconazole, amphotericin B and flucytosine<sup>2, 3, 21)</sup>. Among the medically treated cases in Korea, 3 were treated with itraconazole, and 3 with each of ketoconazole, fluconazole and amphotericin B.

#### Conclusions

Phaeohyphomycosis has so far been known as a rare disease in Korea, since not many cases have been reported due to lack of knowledge of infections caused by dematiaceous fungi. Moreover, phaeohyphomycosis has frequently been mistaken as sporotrichosis of deep mycoses which leads to less interest in identification of the microorganisms. Many cases of phaeohyphomycosis have been reported in Korea since 1996, and more reports of this condition are expected in the near future.

#### Acknowledgement

I thank professor Iwao Takiuchi, President of the 48th Annual Meeting of the Japanese Society for Medical Mycology for extending me an invitation to participate in the International Forum "Mycoses in Asia".

#### References

- 1) Ajello L, Georg LK, Steigbigel RT, Wang CJK: A case of phaeohyphomycosis caused by a new

- species of *Phialophora*. *Mycologia* **66**: 490-498, 1974.
- 2) Kwon-Chung KJ, Bennet JE: Phaeohyphomycosis (chromomycosis, phaeosporotrichosis, cerebral chromomycosis). *In* Medical Mycology, pp.620-677, Lea & Febler, Philadelphia, 1992.
- 3) McGinnis MR: Chromoblastomycosis and phaeohyphomycosis: new concepts, diagnosis, and mycology. *J Am Acad Dermatol* **8**: 1-16, 1983.
- 4) Rinaldi MG: Phaeohyphomycosis. *Dermatol Clin* **14**: 147-153, 1996.
- 5) Dixon DM, Polak-Wyss A: The medically important dematiaceous fungi and their identification. *Mycoses* **34**: 1-18, 1991.
- 6) Nishimoto K: Chromomycosis in Japan. *Korean J Dermatol* **15**: 405-408, 1977.
- 7) Matsumoto T: *Wangiella dermatitidis* infections: a paradigm of the opportunistic mycoses caused by black yeasts and moulds. *Korean J Med Mycol* **5**: 45-50, 2000.
- 8) Jun JB, Suh SB: A case of phomamycosis. *In* Proceedings of the Third Korea-Japan Joint Meeting of Dermatology, pp.163-166, Kyongju, 1983.
- 9) Lee SC, Chun IK, Kim YP: A case of phaeomycotic subcutaneous abscess caused by *Wangiella dermatitidis*. *Korean J Dermatol* **24**: 692-696, 1983.
- 10) Oh SH, Suh SB, Kim SH, Choi SK, Lee HJ, Takatori K: A case of primary subcutaneous phaeohyphomycosis caused by *Drechslera dematioides*. *Korean J Dermatol* **34**: 489-494, 1996.
- 11) Kim HU, Kang SH, Matsumoto T: Subcutaneous phaeohyphomycosis caused by *Exophiala jeanselmei* in a patient with advanced tuberculosis. *Brish J Dermatol* **138**: 351-353, 1998.
- 12) Suh MK, Suh JC, Seo SK, Na GY, Kim YJ, Bang JS, Ha GY, Kim JA, Lee HJ: A case of subcutaneous phaeohyphomycosis caused by *Exophiala jeanselmei*. *Korean J Dermatol* **37**: 359-399, 1999.

- 13) Kim DS, Yoon YM, Kim SW: Phaeohyphomycosis due to *Exophiala dermatitidis* successfully treated with itraconazole. *Korean J Med Mycol* **4**: 79-83, 1999.
- 14) Suh MK, Kwon SW, Kim TH, Sun YW, Lim JW, Lee HJ, Lim SW, Kwon SB, Ha GY, Kim JR: A case of subcutaneous phaeohyphomycosis caused by *Exophiala jeanselmei*. *Korean J Dermatol* **42**: 2004 (in press).
- 15) Ronan SG, Uzoaru I, Nadimpalli V, Guitart J, Manaligod JR: Primary cutaneous phaeohyphomycosis: report of seven cases. *J Cutan Pathol* **20**: 223-228, 1993.
- 16) Boustany S, Green DL, Abadie SM, Zachary JA, Pankey GA: Primary cutaneous phaeohyphomycosis: report of three cases. *J Am Acad Dermatol* **18**: 1023-1030, 1988.
- 17) Guagnani HC, Okeke CN: Physiological characteristics of environmental isolates of pathogenic dematiaceous fungi. *Mycoses* **32**: 78-83, 1989.
- 18) Suh MK, Kim YJ, Kwon SW, Kim JC: Ribosomal DNA gene analysis of dematiaceous fungi using polymerase chain reaction-restriction fragment length polymorphism. *Korean J Dermatol* **41**: 1478-1486, 2003.
- 19) Caligiore RB, Resende MA, Dias-Neto E, Oliveira SC, Azevedo V: Dematiaceous fungal pathogens: analysis of ribosomal DNA gene polymorphism by polymerase chain reaction-restriction fragment length polymorphism. *Mycoses* **42**: 609-614, 1999.
- 20) Caligiore RB, Resende MA, Palva E, Azevedo V: Use of RAPD (random amplified polymorphic DNA) to analyse genetic diversity of dematiaceous fungal pathogens. *Can J Microbiol* **45**: 408-412, 1999.
- 21) Chuan MT, Wu MC: Subcutaneous phaeohyphomycosis caused by *Exophiala jeanselmei* successful treatment with itraconazole. *Int J Dermatol* **34**: 563-566, 1995.

---

This article was presented as a special lecture in the 48th Annual Meeting of the Japanese Society for Medical Mycology's International Forum "Mycoses in Asia".